

Neurological Manifestations of Covid-19: A Comprehensive Review

Naseem Ahmed^{1*}, Lahiba Rasheed Khan², Rabia Rasool², Amna Imran², Maria Noor²

¹Department of Pathology, Dow Medical College Karachi, Pakistan.

²Dow Medical College, Karachi Pakistan

ABSTRACT

The COVID-19 pandemic causing virus, SARS-CoV-2 emerged in the year 2019 from China. Since then, it has inflicted millions of people globally. Common presentations include cough, fever, body ache, fatigue, and shortness of breath, whereas few people might not develop any symptom. The main target of this virus is respiratory system; precisely it attacks the ACE-2 receptors of alveolar cells of lungs. ACE-2 receptors are also found in heart, gastrointestinal tract, kidneys, testis, and brain; hence involvement of these organs is also seen with this disease. An emerging discovery of invasion of nervous system by this virus has impelled researchers to investigate and understand the neurological mechanisms and features of COVID-19. The virus can affect Central as well as Peripheral Nervous System. Peripheral nervous system implications are not critical and include hypersomnia, ageusia, Guillain barre syndrome, paresthesia, skeletal muscle injury and cranial nerve involvement, whereas in central nervous system, dizziness, headache, acute cerebrovascular disease, altered level of consciousness, transverse myelitis, acute hemorrhagic necrotizing encephalopathy, encephalopathy, encephalitis, epilepsy and ataxia can develop. Neurological manifestations are particularly seen with severely ill COVID patients.

In this article, we present a comprehensive review of prevalence of various CNS and PNS symptoms in COVID-19, risk factors, investigations, management, and prognosis related to these. This will aid the physicians and neurologists in better understanding the course of this illness and the current statistics of neurological presentations, crucial for handling the disease.

Keywords: Neurological complications, SARS-Cov-2, Neurological signs, Neurological symptoms, Covid-19, Novel Coronavirus.

Available Online: 31st December 2021

Article History

Received: 20.10.2021

Accepted: 11.11.2021

*Corresponding Author

Prof. Dr. Naseem Ahmed

Professor of Pathology

Dow Medical College, Karachi, Pakistan

Email: drnasim@hotmail.com

Copyright: © the author(s). IABCR is an official publication of Ibn Sina Academy of Medieval Medicine & Sciences, registered in 2001 under Indian Trusts Act, 1882.




This is an open access article distributed in accordance with the Creative Commons Attribution Non Commercial (CC BY-NC 4.0) license, which permits others to distribute, remix, adapt, build upon this work non-commercially, and license their derivative works on different terms, provided the original work is properly cited and the use is non-commercial

INTRODUCTION

Coronavirus disease 2019 (COVID-19) is caused by a novel coronavirus termed as "severe acute respiratory syndrome". It's outbreak emerged in the year 2019 from the Wuhan city, China,^{1,2} as unusual cases of pneumonia with an unknown cause.³ It was proclaimed as a pandemic disease on March 11th, 2020 by World Health Organization (WHO).⁴ To this date (29th April 2021) more than 149,216,984 people have been infected worldwide and more than 3,144,028 people have died due to COVID-19.⁵ To overcome this outbreak a great amount of research is being conducted regarding its identification and medical therapy. Studies report a broad spectrum of presentations which include nonproductive cough, fever, myalgia, fatigue, dyspnea, diarrhea, and nausea/vomiting, whereas few patients remain symptomless.⁶ Even though COVID-19 predominantly

involves the respiratory and cardiovascular system, 35% of the patients are prone to develop neurological symptoms including headache, dizziness, hypogeusia, and neuralgia.^{7,8} In some patients, neurological manifestations are the part of the initial presentation,⁹ but mostly these are prevalent in patients with severe disease.¹⁰

In this study we present a comprehensive review of the neurological manifestations of COVID-19. Consequently, neurological presentations were bifurcated into Central Nervous System and Peripheral Nervous System symptoms. Objective of our study is to upgrade the health care professionals about the neurological manifestations of this novel Corona virus infection.

Access this article online	
Website: www.iabcr.org	Quick Response code 
DOI: 10.21276/iabcr.2021.7.4.5	

How to cite this article: Ahmed N, Khan LR, Rasool R, Imran A, Noor M. Neurological Manifestations of Covid-19: A Comprehensive Review. Int Arch BioMed Clin Res. 2021;7(4):PA1-PA9.

Source of Support: Nil, **Conflict of Interest:** None

PATHOPHYSIOLOGY AND CLINICAL ASPECTS OF COVID 19:

The central receptor for the introduction of this infectious agent into cells is Angiotensin Converting Enzyme (ACE-2). After binding of Spike (S) protein of SARS-CoV-2 to ACE-2 receptor, a conformational change in S protein occurs, which leads to fusion of viral envelope with the cell membrane. Genome RNA is released into the cell which then undergoes translation leading to production of protein peptides pp1a and 1ab. These polypeptides are further degraded into smaller proteins by viral enzymes. Additional sub genomic mRNAs are translated into pertinent viral proteins. In the endoplasmic reticulum and golgi apparatus assembly of virion takes place, carried by vesicles towards the cell membrane and released out of the cell.¹¹

ACE-2 receptors can be found in the heart, lungs, gastrointestinal tract, kidneys, testis, and brain. The primary site of infection is lungs since ACE-2 receptors are expressed mainly in type 2 alveolar cells of lung. The broad surface of alveolar cells might describe why this organ is vulnerable to damage by SARS-CoV-2 invasion.¹²

A study conducted by Wei-jie Guan et al. on 1099 laboratory confirmed COVID-19 cases, delineated the following clinical manifestations of COVID-19: - Fever (88.7%), cough (67.8%), sore throat (13.9%), sputum (33.7%), fatigue (38.1%), shortness of breath (13.7%), vomiting (5%), diarrhea (3.8%), myalgia (14.9%), and headache (13.6%). Complications developed during hospital admission include septic shock (1.1%), acute respiratory distress syndrome (3.4%), acute kidney injury (0.5%), disseminated intravascular coagulation (0.1%), rhabdomyolysis (0.2%), and physician diagnosed pneumonia (91.1%).¹³

Plasma levels of interleukin 7 (IL-7), interleukin 10 (IL-10), interleukin 2 (IL-2), Granulocyte-colony stimulating factor (G-CSF), Inducible protein IP10, monocyte chemoattractant protein-1 (MCP-1), macrophage inflammatory protein-1 α (MIP-1 α), and tumor necrosis factor- α (TNF- α) were comparatively elevated in critically ill patients than non-ICU patients suggesting an underlying hypercytokinemia associated with disease severity. In patients with severe illness, corticosteroids were proved to be beneficial in reducing symptoms, as they decrease inflammation mediated organ damage.¹⁴

TRIGGERING MECHANISMS OF NEUROLOGIC DAMAGE IN COVID -19:

MECHANISM OF PNS INJURY IN COVID-19:

Chemosensory disturbances such as anosmia and ageusia constitute the main PNS manifestations of COVID-19. The mechanism behind these chemosensory disturbances is briefly described here and outlined in *figure 1*. The model proposed for anosmia is that this virus mainly infects sustentacular cells in the olfactory epithelium, followed by desquamation. The presence of debris in the nasal cavity is indicative of this desquamation. This desquamation process will remove part of the olfactory sensory neurons population and could be accompanied by loss of dendrites of these neurons, where sensory perception occurs leading to anosmia.¹⁵

The taste buds are renewed after approximately every 10 days. One mechanism for ageusia could be that after infection of taste bud cells, inflammatory cytokines invade the taste buds and impair their regeneration. Toll-like receptors and interferon receptors are highly expressed in taste buds,

thus their activation upon contacting the SARS-CoV-2 virus limits taste bud cells renewal and leads to ageusia. Another hypothesis proposed is that damage to cranial nerve fibers concerned with taste(gustation) after invasion of the CNS by SARS-CoV-2 can trigger ageusia. This hypothesis seems to be dubious as many patients developing ageusia had low-severity symptoms without any evidence of CNS involvement.¹⁵

MECHANISM OF CNS INJURY IN COVID-19:

Possible mechanisms for the entrance of SARS-COV-2 into cells as depicted in the flowchart (*figure 2*) are as follows: The first route is hematogenous and the second is retrograde dissemination of the virus through neurons.¹⁶ In the hematogenous route, SARS-CoV-2 with its spike protein binds to ACE-2 receptors expressed in the capillary endothelium of the blood brain barrier (BBB), neurons and glial cells of the brain especially brainstem and cardiovascular regulatory areas like nucleus tractus solitarius, paraventricular nucleus and rostral ventrolateral medulla. Next, viral particles bud inside capillary endothelium, causing endothelial damage which favors viral entry in the brain.^{17,18} The second route is implicated in hyposmia in which the virus enters the olfactory bulb of the brain along the olfactory nerve.¹⁶

As stated above, the binding of SARS-CoV-2 with ACE-2 receptors promotes the processes of inflammation, coagulation, and apoptosis in vascular endothelial cells of brain thereby increasing the risk of stroke, transient ischemic attack, sub cortical bleeds, micro thrombi, arterial thrombi, venous thrombi, and ischemic infarcts. This hypercoagulable state is due to the elevation of pro-inflammatory cytokines such as TNF α , IL-1 β , IL-6, G-CSF, GM-CSF (Granulocyte-Macrophage Colony Stimulating Factor), and chemokines like MCP-1, IP-10 and MIP-1 α . This rapid release of large amounts proinflammatory cytokine cause 'cytokine release syndrome or hypercytokinemia' which presents with high grade fever, headache, hypotension, night sweats and multiorgan dysfunction.¹⁹ This high level of circulating cytokines is also associated with confusion and altered level of consciousness.²⁰ The cytokine storm also causes an alteration in the normal blood coagulation by increasing D-dimer levels, a fibrin degradation product, thereby exerting a pro-coagulant effect.²¹ Recent studies also suggest the outcome of this infection on platelets as thrombocytopenia has been identified in those afflicted from severe COVID-19.²²

Seizure, another manifestation of COVID-19 is proposed to be due to the direct penetration of brain by this infectious agent and by the production of toxins and inflammatory mediators by the virus once it is inside the brain parenchyma.²³ The above-mentioned factors along with some other indirect factors such as hypoxia, dehydration, systemic inflammation and metabolic imbalances are linked to headache recognized in patients affected from COVID-19.²⁴ The hyperinflammatory state mentioned above is also the likely cause of para-infectious ataxia. Whereas post-infectious ataxia is most likely due to the formation of autoantibodies directed against Purkinje cells, striatal neurons, and hippocampal neurons.²⁵

Figure 1: Proposed mechanism of Peripheral Nervous System invasion by SARS-Cov-2.

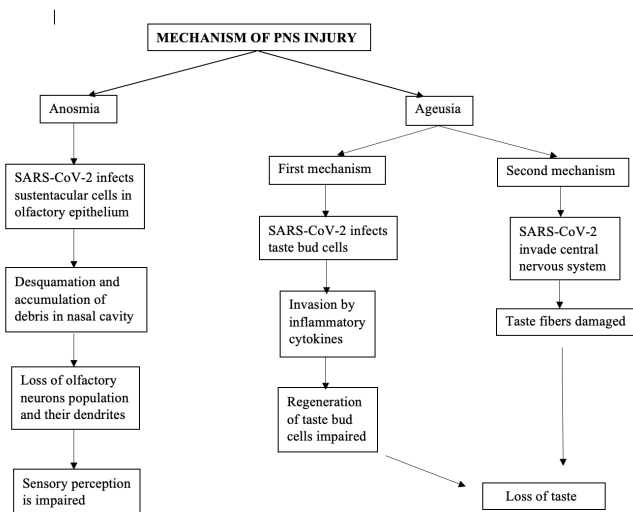
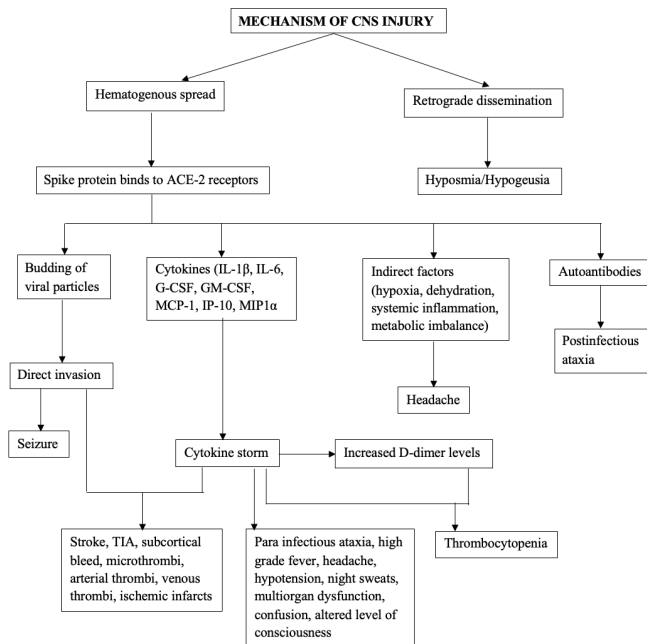


Figure 2: Possible mechanisms of injury in Central Nervous System by SARS-Cov-2.



DISCUSSION

PNS related signs and symptoms in COVID-19

Prevalence of PNS symptoms in COVID-19:

A study done in the early time period of the disease i.e., initial months of 2020, on 214 hospitalized patients in Wuhan province of China from where the virus first emerged, showed few and less severe PNS symptoms, which were less prevalent than the CNS symptoms.¹⁰ These PNS features include hyposmia/anosmia, hypogeusia/ageusia, nerve pain, and vision impairment.¹⁰ Later, in a case study, Guillain Barre syndrome was reported in a patient tested positive for COVID-19.²⁶ Myalgia and paresthesia have also been seen in COVID-19 patients.²⁷ Myositis/rhabdomyolysis are the other neuromuscular complaints found in this disease.²⁸ These symptoms as described in different studies are discussed here and summarized in Table 1 below. Hyposmia or anosmia is a very common presentation. During an observational study by Klopfenstein T et al. in France in

March 2020, 47% COVID-19 affected patients with its definitive diagnosis showed the symptom of anosmia. Participants of this study included both hospitalized and ambulatory patients but had fewer comorbidities and mainly were middle aged adults. 98% recovery rates from anosmia were observed at the end of study.²⁹ A higher prevalence of anosmia/hyposmia; 85.6%, was seen in another European study on 417 patients having similar co-morbidity profile and age bracket. Recovery from this ENT symptom was evident.³⁰ Kim GU et al. delineated the occurrence of hyposmia in an Asian group of population where its prevalence was seen as 39.5%, it was associated with other symptoms in 90% of the patients. Interestingly, hyposmia was even more common than fever.³¹ 646 patients with a confirmed diagnosis of COVID-19 were included in a retrospective observational study for the evaluation of neurological implications in Tunisia, North Africa, out of which 37.9% patients reported smell dysfunction. Smell impairment was not associated with nasal obstruction.³² These studies showed anosmia as a highly prevalent symptom of COVID-19, usually appearing as a second or third symptom during the illness but with a good outcome and associated with a mild to moderate disease course.³⁰⁻³²

Table 1. shows prevalence rates of these PNS symptoms in different studies throughout the world.

SIGN AND SYMPTOM	STUDY	COUNTRY	SAMPLE SIZE	PATIENTS WITH SIGN AND SYMPTOMS	FREQUENCY
Hyposmia/ Anosmia	Klopfenstein T et al. ²⁹	France	114	54	47%
	Lechian JR et al. ³⁰	Europe	417	357	85.6%
	Kim GU et al. ³¹	South Korea	172	69	39.5%
	Kacem I et al. ³²	Tunisia	646	245	37.9%
Hypogeusia/ Ageusia	Lechian JR et al. ³⁰	Europe	385	342	88.8%
	Kacem I et al. ³²	Tunisia	646	238	36.8%
	Patel A et al. ³³	London	141	89	63.1%
Guillain Barre Syndrome	Romero-Sanchez CM et al. ³⁴	Spain	841	1	0.12%
Myalgia	Kacem I et al. ³²	Tunisia	646	241	37.3%
	Patel A et al. ³³	London	141	93	66%
	Gomez-Belda AB et al. ³⁵	Spain	340	113	33.2%
Paresthesia	C. Ligouri et al. ²⁷	Italy	103	6	5.8%
	Samar I et al. ³⁷	Pakistan	350	11	3.1%
Skeletal Muscle injury	Ling Mao et al. ¹⁹	China	214	23	10.7%

Ageusia/dysgeusia in COVID-19 is strongly associated with smell impairment. Klopfenstein T et al. survey described a significant relation between the two symptoms with 85% of patients with anosmia developing dysgeusia too.²⁹ Similarly, strong association was appreciated between smell and taste dysfunction (p<0.001) in the multicenter European study. The prevalence rate of dysgeusia was 88.8%.³⁰ The study of Kacem I et al. in Tunisia also showed simultaneous occurrence of olfactory and gustatory dysfunction in 31.4% patients.³² While studying the 141 confirmed cases of COVID-19 in UK for the prevalence of anosmia and ageusia, 63.1% reported ageusia. The study concluded that anosmia and ageusia are powerful predictors of COVID-19.³³

Therefore, the presence of these should raise high suspicion of this infection, especially when not associated with nasal obstruction.^{32, 33}

Table 2. summarizes the CNS manifestations and their incidence in patients with COVID-19

SIGN AND SYMPTOM	STUDY	COUNTRY	SAMPLE SIZE	PATIENTS WITH SIGN AND SYMPTOMS	FREQUENCY
Headache	Mao et al. ¹⁰	China	214	28	13.1%
	Flores-Silva et al. ⁵¹	Mexico	1072	447	41.7%
	Uygun Ö et al. ⁵²	Turkey	3458	87	33.2% (in 262 Covid-19 positive patients)
Dizziness	Mao et al. ¹⁰	China	214	36	16.8%
	Saniasiaaya J et al. ⁵⁵	Review article (China, Turkey, USA, Canada, Italy)	1074	141	13.12%
Altered level of consciousness	Mao et al. ¹⁰	China	214	16	7.5%
Cerebrovascular disease	Hernández-Fernández F et al. ⁶⁰	Spain	1683	23	1.4%
	Guan WJ et al. ¹³	China	1099	11 (Non severe), 4 severe	1.2% (Non severe), 2.3%
	Zhang JJ et al. ⁶¹	China	140	3	2.1%
	Aggarwal G et al. ⁶²	China	2031	55	2.7%
Seizure	Mao et al. ¹⁰	China	214	1	0.5%
	Lu L et al. ⁶⁵	China	304	2	0.65%
Ataxia	Mao et al. ¹⁰	China	214	1	0.5%
Encephalopathy	Meppiel E et al. ⁶⁷	France	222	85	38.3%
	Scullen T et al. ⁶⁸	USA	76	20	74%
Encephalitis	Meppiel E et al. ⁶⁷	France	222	21	9.5%
	Varatharaj A et al. ⁶⁹	UK	153	7	44% (out of 16 patients with encephalopathy)

Guillain barre syndrome has also come into consideration to be accompanied with this infection. The first case report on GBS is of a 65-year-old male patient, with type 2 diabetes mellitus, who presented with 5 days history of progressive weakness in distal lower limbs. Weaknesses ascended to proximal limbs and involved all four limbs. Bilateral facial paresis was noted. Deep tendon reflexes were absent. He had no spine sensory level and reduced vibration and fine touch senses below ankle joint. Fever, urinary and fecal incontinence were absent. Blood pressure, respiratory rate, heart rate, oxygen saturation and labs were normal. Erythrocyte sedimentation rate (ESR) was raised and C-reactive protein 2+. GBS diagnosis was made on nerve conduction studies and electromyography. Two weeks prior to this presentation, he had cough, fever and dyspnea and was confirmed with SARS CoV-2 infection by Reverse Transcriptase PCR and chest CT.²⁷ 841 Spanish confirmed COVID-19 hospitalized patients were a part of an observational study that aimed to evaluate neurological manifestations in such patients. The prevalence of GBS came out to be 0.12%, one of the three least prevalent symptoms among the neurological manifestations in this survey, other two being optic neuritis (0.12%) and encephalitis. However, this study was carried out in the beginning of the pandemic.³⁴ Rahimi K et al. published a

review of total 31 known cases of GBS linked to COVID-19 throughout the world up till August 2020. Among these, 29 cases developed GBS following a SARS CoV-2 infection reflecting the typical post-infectious pattern, whereas 2 cases had GBS and COVID-19 at the same time reflecting the para-infectious pattern. This Para infectious onset of GBS has been seen with Zika virus previously. The most common subtype of GBS seen with COVID-19 was acute inflammatory demyelinating polyneuropathy or AIDP. There was only 1 child patient while majority were older adults supporting the idea that GBS is more common in older and male population.³⁵ Hence, these data suggest that Guillain barre syndrome can be related to COVID-19, but a rare presentation.

Myalgia is a nonspecific but another very common symptom of COVID-19. The African survey by Kacem et al. demonstrated the incidence of muscle ache as 37.3%, being one of the four main neurological complaints in this study. It was observed early during the infection and was most commonly generalized in nature. However, limb and trunk myalgia were frequent too.³² The frequency of muscle pain was 66% in London survey by Patel A et al. with it being more frequent in community diagnosed than hospitalized patients.³³ Gomez Belda AB et al. compared the neurological symptoms in elderly and young patients. The results showed that myalgia was more common in the non-elderly group i.e., 41%. The frequency of myalgia in elderly was 23.7% and prevalence of myalgia in total sample size was found to be 33.2%.³⁶

Ligouri C et al. while evaluating subjective neurological symptoms in COVID-19 patients found that paresthesia occurred in 5.8% of their participants, all of whom were females. Moreover, it appeared along with at least 2 other neurological complaints and never alone.²⁷ A cross sectional study carried out in Pakistan to assess the prevalence of neurological characteristics indicated the presence of paresthesia in Corona virus infected population. It was the 3rd most common neurological complaint after headache and vertigo, present in 3.1%.³⁷ A case of peripheral neuropathy associated with COVID-19 was reported in a 40-year-old woman two weeks after her diagnosis of COVID-19. She complained of sudden onset, severe, intermittent lower back and hip pain with numbness and weakness. On examination she had symmetrical non-ascending weakness in both lower limbs, but deep tendon reflexes were intact. Power was 4/5 and sensory ataxia was noted. Her labs were normal except for slightly raised serum lactate dehydrogenase, low vitamin B6 and mild reduction in serum copper. Authors concluded that this case was different from GBS and vitamin B6 deficiency. She was treated with intravenous steroids, intravenous immunoglobulin, gabapentin, duloxetine, tramadol, rehabilitation, and copper replacement.³⁸

Paliwal VK et al. published a review on neuromuscular presentations in SARS CoV-2 infected patients. Besides describing myalgia, GBS, myasthenia gravis, olfactory, gustatory, and cranial manifestations, they discussed rhabdomyolysis/myositis related to COVID-19 in 9 male patients. These patients presented with different clinical characteristics including myalgia and limb/generalized weakness. All of them had raised creatinine phosphokinase (CPK) levels, serum ferritin and LDH. Three patients did not have respiratory involvement.²⁸ Skeletal muscle injury was reported to be associated with severe infection with increased liver and kidney damage in Wuhan study on

hospitalized patients. The incidence of muscle injury in the total sample size was 10.7%.¹⁰

In cranial nerves, there are reports of involvement of optic, oculomotor, facial, and cochlear nerves.^{39,40} There had been a case report of hearing impairment, ageusia and anosmia along with dyspnea on exertion for 3 days in a 61-year-old lady with a positive contact history of SARS-CoV-2. She was admitted for supportive treatment and 3 days later diagnosis of COVID-19 was confirmed with a positive swab test.⁴¹ Another case with similar triad of hearing, smell, and taste loss with a positive contact history but in a younger patient with longer duration of history was seen. The 18-year-old female reported 7 weeks of bilateral sudden sensorineural hearing loss (SSNHL) with nausea, vomiting, vertigo, ageusia and anosmia. Other risk factors for hearing loss were absent. Serum COVID-19 IgG were detected 10 weeks after the onset of her symptoms.⁴² However, while commenting on Kilic et al. article about relation of SSNHL with COVID-19 where only 1 out of 5 patients with hearing complaint was COVID positive; Luca PD et al. said that there was not enough evidence to support the notion that hearing loss could occur with this disease. The authors argued that the present-day published writings available does not provide a solid link between COVID-19 and hearing impairment and thus it is not an established finding yet.⁴³

Risk factors of PNS symptoms in COVID-19:

Neurological presentations are more prevalent in hospitalized patients and severe infection.^{10,32,34} As noted in studies, female and younger patients tend to be affected more with impaired smell sensation.³⁰⁻³²

Investigations of PNS symptoms in COVID-19:

Standard laboratory investigations are carried out in neurological patients of COVID-19 including complete blood count (CBC), CRP, D-dimer, creatinine kinase, lactate dehydrogenase, aminotransferase, alanine, aspartate, BUN, and creatinine. In Wuhan study of hospitalized patients there were no noteworthy difference in the labs of positive PNS symptoms patients and negative PNS symptoms patients.¹⁰ Higher creatinine kinase levels are seen in SARS-CoV-2 positive patients with muscular symptoms compared to SARS-CoV-2 negative patients.⁴⁴

Management of PNS symptoms in COVID-19:

For GBS, IVIG treatment is gold standard and has shown good results in GBS linked to COVID-19,^{26,35} thus this usual treatment is followed for these patients. There are no standard treatments for most PNS symptoms occurring in COVID-19 like anosmia and ageusia, these may resolve on their own. In case of muscle involvement nutritional support is advised.⁴⁵

Prognosis of PNS symptoms in COVID-19:

As stated earlier, anosmia has good prognosis and recovery rates are high.^{29,30} However, a retrospective cohort study conducted to evaluate new onset headaches during COVID-19 demonstrated that anosmia and ageusia may persist. In this study, patients were followed 1 month after their symptoms had disappeared via teleconsultation. Besides the finding of new onset headaches, the study reported the persistence of anosmia and ageusia in 14.4% and 11.5%, respectively.⁴⁶

Long-COVID is a term used to describe COVID-19 symptoms extending beyond 6 weeks of duration.⁴⁷ Persistence of muscle weakness was observed in 63% of the long haulers in Huang C et al. study done in China, and this was the most common complaint. These patients were

interviewed after 6 months of their discharge from hospital and the incidence of fatigue was higher in severely ill patients.⁴⁸

Concerning the prognosis of GBS we see that in review of GBS case reports by Rahimi K et al. 5 out of 31 cases were shifted to ICU³⁵ and a detailed review covering 73 GBS cases from all the continents except Australia by Abu-Rumeilah S et al. showed 72.1% improvement rates; prognosis data was available for 68 instead of 73 cases. Management data was available for 70 cases in which 21.4% required ventilation support due to increasing GBS severity.⁴⁹ Hence GBS with COVID-19 also has a good prognosis.

Overall, PNS symptoms associated with COVID-19 have a favorable prognosis. Nevertheless, follow up must be performed to assess and manage the long-term neurological consequences.

CNS related signs and symptoms in COVID-19

Prevalence of CNS symptoms in COVID-19 patients:

Dizziness, headache, acute cerebrovascular disease, altered level of consciousness, cerebrovascular disease, transverse myelitis, acute hemorrhagic necrotizing encephalopathy, encephalopathy, encephalitis, epilepsy, and ataxia are the main CNS manifestations of COVID-19.⁵⁰ They are summed up in Table 2 below.

In a retrospective, observational study conducted on a total of 214 patients hospitalized in Wuhan, China, 36.4% patients developed nervous manifestations. Out of these 24.8% patients had central nervous symptoms.¹⁰ In another prospective, cross-sectional, observational study on 1072 adult hospitalized patients of 18 years of age or more in Mexico City, 15.2% patients developed a new neurological complication.⁵¹

According to the study conducted by Flores-Silva et al., headache was the most common neurological manifestation in 41.7% COVID-19 positive patients at the time of admission.⁵¹ Uygun Ö et al. while studying the headache characteristics and its association in COVID-19 patients reported that 33.2% patients out of 7.96% COVID-19 positive patients developed new onset headache, whereas 44.3% patients had previous headache. Out of these COVID-19 positive patients, 26.6%, 47.7%, 23.4%, and 2.3% (3) participants complained of mild, moderate, severe, and very severe headache, respectively. These headaches were bilateral, analgesic resistant, lasted >72 hours, were more common in males and were associated with anosmia, ageusia, and gastrointestinal symptoms.⁵² Another study conducted by Sampaio Rocha-Filho PA et al. on 73 patients admitted in a hospital in Brazil reported 64.4% patients experienced headache associated with COVID-19.⁵³ Most patients complained of experiencing a headache on first day of symptom onset. The headache was associated with cough in 16.4% patients in whom the headache was of migraine and tension type headache phenotype. 15% patients complained of continuous headache while those with non-persistent headaches experienced episode of 120 minutes. The headache in this study was also associated with hyposmia/anosmia and hypogeusia/ageusia in 38.4% and 39.7% patients, respectively.⁵³

On the other hand, Mao et al. reported that dizziness was the most common neurologic symptom (16.8%), headache being the second most prevalent (13.1%).¹⁰ The first case that reported dizziness as the presenting complaint of SARS-CoV-2 infection was in a 53-year-old female from China. She

presented with a 3 dayshistory of sudden dizziness along with dry throat. She was tested positive for Novel Corona virus on 5th day of admission.⁵⁴ Routine blood test showed an elevated number of neutrophils and a reduction in the number of lymphocytes. Chest CT also showed areas of high density especially in extrapulmonary areas. Urine test, lumbar puncture, Brain MRI, pure tone threshold, electronystagmography, and CT angiography of head and neck were normal.⁵⁴ Saniasiaya J et al. studied 141 patients from 14 articles who had dizziness as their presenting complain. These studies, however, did not investigate this symptom thoroughly and its investigation and treatment, and outcome were discussed in 2 and 1 studies, respectively.⁵⁵ The investigations in the first study were electronystagmography, pure tone threshold, brain MRI and the treatment given was betahistine, danshenuchuanomazine. The investigations in the second study were bedside neurological examination, brain CT and the treatment given was meclizine, benzodiazepine, steroids, vestibular rehabilitation which resolved the symptom.⁵⁶ Mao et al. also reported 7.5% patients who complained of impaired consciousness during the disease. Of these affected individuals, 14.8 had severe disease while 2.4% had non-severe disease.¹⁰ Kotfis K et al. in another review article proposed that the incidence of delirium was high in severely ill elderly patients admitted in intensive care unit (ICU) and that it was pertained to several factors. These factors included social and epidemiological factors like isolation, quarantine, and increased burden of work among health care professionals, type of medications and treatment given to the patient, and psychological factors like fear, anxiety, and disorientation.⁵⁷ Guan WJ et al. while studying a sample population of 1590 patients in China found that unconsciousness was associated with comorbidities like COPD, diabetes, hypertension, cardiovascular disease, cerebrovascular disease, and hepatitis B infection.⁵⁸ Stroke or cerebrovascular disease is a rather infrequent but deadly manifestation of SARS-CoV-2 infection. It occurs in 1-3% and 6% of hospitalized patients and patients admitted in ICU, respectively.⁵⁹ Hernández-Fernández F et al. in a single center retrospective analysis done on 1683 patients admitted in a hospital reported that 1.4% patients developed cerebrovascular disease. In this subset of patients, the stroke typically developed 5 days after the onset of COVID-19 symptoms. These patients were further subclassified according to the type of cerebrovascular disease they developed. These included cerebral ischemia, intracerebral hemorrhage, and posterior reversible encephalopathy syndrome (PRES)-type leukoencephalopathy in 73.9%, 21.7%, and 4.3% patients, respectively. The mean age of the patients who developed cerebrovascular disease was 66.9 years and the study also showed a high incidence of disease in male smokers with comorbidities like hypertension, type 2 diabetes mellitus, dyslipidemia, ischemic heart disease, atrial fibrillation, and COPD.⁶⁰ While studying 1099 cases of COVID-19 positive patients from 522 hospitals from 30 provinces of China, Guan WJ et al. reported that 1.2% out of 84.2% patients with non-severe disease and 2.3% out of 15.7% patients with severe disease developed cerebrovascular disease. The median age of the patients was 47 (35-58) years and the outcomes in this subset of patients were admission in intensive care unit, mechanical ventilation, and death.¹³ Zhang JJ et al., studied a total of 140 patients with a median age of 57 (25-87) years. 2.1% patients

developed stroke. Of these 3 patients, 1.2% had non-severe disease while the other 3.4% had severe disease. In this subset of patients, the two most prevalent comorbidities were hypertension (30%) and diabetes mellitus (12.1%).⁶¹ In a pooled analysis of published literature done by Aggarwal G et al. which overviewed a sample population of 2031 in 6 different studies, it was established that cerebrovascular disease correlated with a statistically significant increased risk of severe form of COVID-19 (~2.5-fold increase).⁶² Oxley TJ et al. published a study which described stroke in individuals below the age of 50 (33, 37, 39, 44, 44 years). 4 of these 5 patients were males and 1 was female. 2 patients did not have any comorbid conditions while the remaining 3 had hyperlipidemia, mild stroke, hypertension, and diabetes. The mean National Institute of Health Stroke Scale (NIHSS) was 17. The investigations included CT, CTA, computed tomography perfusion (CTP), MRI, and the treatment modalities included apixaban, aspirin, intravenous t-PA, clopidogrel, clot retrieval, stent, and hemicraniectomy.⁶³ Mao et al. in their case series also reported 0.5% (1) patient with severe disease who developed seizures.¹⁰ One more case of seizure was reported in a 30-year-old female from Iran with no known comorbidities. The woman developed generalized tonic clonic seizures on 5th day of the onset of generalized symptoms of COVID-19 like dry cough, fever, and fatigue. The first episode of seizure occurred 2 days before admission in the hospital and thereby continued to occur at least 5 times a day and approximately 8 hours apart. The chest CT showed focal ground-glass opacities, whereas all the other laboratory investigations were unremarkable. The patient was given intravenous phenytoin and levetiracetam which helped control the seizures.⁶⁴ A retrospective multicenter study conducted by Lu L et al. on 304 patients reported seizures in 2 females of ages 32 and 65 years. The latter developed the symptom due to metabolic abnormalities which was resolved by correcting the metabolic disturbance.⁶⁵ Mao et al. also reported 0.5% (1) patient with severe disease to develop ataxia.¹⁰ The first case of ataxia in a COVID-19 positive patient was reported by Diezma-Martín AM et al. The patient was 70 years old with a history of COPD. Ataxia was developed along with tremor on 17th day of symptom onset. Baseline laboratory investigations, CSF analysis, and brain MRI showed no evidence of disease. The symptom was initially thought to be a consequence of treatment with corticosteroids and beta-adrenergic drugs, but it did not resolve when these drugs were withdrawn. Clonazepam caused a slight improvement of symptom.⁶⁶ Meppiel E et al. conducted a retrospective, single-center observational study on 222 hospitalized patients in 46 hospitals in France and reported that 38.3% patients had encephalopathy, 28.4% had stroke, 9.5% had encephalitis.⁶⁷ Scullen T et al. conducted a single-center cross-sectional analysis of 76 patients in Louisiana. The mean age of the patients was 59.8 years and the predominant comorbid conditions that these patients had were hypertension, type 2 diabetes mellitus, obesity, and chronic kidney disease. 74% patients were diagnosed with COVID-19 associated encephalopathy. This diagnosis was established based on EEG, brain CT and/or brain MRI.⁶⁸ Varatharaj A et al. while conducting a survey of 153 cases in UK reported 16 patients with encephalopathy. Out of these 16 patients, 44% (7) patients showed signs of CNS inflammation and met the criteria for clinical diagnosis of encephalitis.⁶⁹ A few

postinfectious syndromes are also associated with COVID-19 patients. These include, acute demyelinating encephalomyelitis (ADEM), acute hemorrhagic encephalitis (AHE), acute hemorrhagic necrotizing encephalopathy, and transverse myelitis. The first case of postinfectious acute transverse myelitis was published by Durrani et al. in a case report. The patient was a 24-year-old male with no known comorbidities. He came to hospital with the complaint of general COVID-19 symptoms and his nasopharyngeal swabs were tested positive for SARS-CoV-2 on RT-PCR. He was admitted in hospital for 3 days and was given symptomatic treatment. He then presented 9 days later with bilateral lower limb weakness with overflow urinary incontinence. He had bilateral knee and ankle reflexes, and bilateral lower extremity flaccid paraplegia. Other neurological findings were unremarkable. MRI spine showed hyperintense signal abnormality seventh to twelfth thoracic vertebra, a finding associated with acute transverse myelitis. Lumbar puncture also showed lymphocytic pleocytosis. The patient was then given IV methylprednisolone which improved the bilateral lower limb strength.⁷⁰ Poyiadji et al. reported the first case of acute hemorrhagic necrotizing encephalopathy in a female airline worker in her late fifties. The patient presented with cough, fever, and altered mentation for 3 days. Nasopharyngeal swab was done, and she was tested positive for COVID-19. Non-contrast CT of head showed symmetric hypoattenuation of bilateral medial thalami. Whereas MRI showed hemorrhagic rim enhancing lesion in bilateral thalami, medial temporal lobes, and subinsular region. CSF cultures were negative for any other causative agent and CT angiogram and venogram were normal as well. The patient was given intravenous immunoglobulin. This case of ANE was thought to be caused by cytokine storm.⁷¹ A 53-year-old man was hospitalized after developing general symptoms of COVID-19. His condition deteriorated rapidly, and he was admitted in the critical care unit the next day. He was diagnosed with ADEM 59 days later for which he was given intravenous methylprednisolone followed by prednisolone. His case was later followed up neurorehabilitation unit. The investigations included MRI of brain and orbits with gadolinium (multiple bilateral hyperintense lesions in subcortical and deep white matter of frontoparietal lobes), fluid-attenuation recovery sequence (FLAIR) (sulcal hyperintensities in parieto-occipital lobes, susceptibility-weighted imaging sequence (parenchymal microhemorrhages in frontal, parietal, and occipital lobes), elevated D-dimer, oligoclonal bands in both CSF and serum, diffuse slowing with transient sharp theta waves in EEG, reduced visual acuity, and marked colour deficit in Ishihara test.⁷² Chaumont et al. reported a COVID-19 patient with meningoencephalitis. His symptoms were fever, cough, altered level of consciousness, confusion, severe headache, neck stiffness, anosmia, ageusia, cervical pain, inability to walk, dyspnea, and diarrhea. Laboratory investigations showed increased C-reactive protein, creatinine kinase, lactate dehydrogenase, and liver enzymes. CSF was purely lymphocytic, and EEG showed bilateral slowed activity. Chest CT was highly suggestive of COVID-19. SARS-CoV-2 was not detected in nasopharyngeal swab or CSF but was present in bronchopulmonary lavage. The treatment modalities included nasal oxygen therapy, acyclovir infusions, hydroxychloroquine sulfate, and azithromycin. His symptoms

improved with time although he had mild symptoms when he was discharged.⁷³

Risk factors of CNS symptoms in COVID-19 patients:

Old age and critical illness are two important risk factors for delirium in COVID-19 positive patients.⁵⁷ Other modifiable risk factors include excessive use of benzodiazepines for sedation and a decrease in the number of visits from family members of admitted patients.⁷⁴ A cross-sectional study demonstrates female gender, history of headache disorders, fever, dehydration, malignancy, decreased platelets and hemoglobin levels and an increase in neutrophil to lymphocyte ratio (NLR) and CRP as important risk factors for headache associated with COVID-19.⁷⁵ Old age, race other than Caucasian, need for mechanical ventilation and use of anticoagulants can lead to intracerebral hemorrhages in COVID-19 patients.⁷⁶ Other important risk factors for stroke were severely ill male smokers who were admitted in ICU and had comorbid conditions like hypertension, type 2 diabetes mellitus, dyslipidemia, ischemic heart disease, atrial fibrillation, and COPD.^{59, 60} Lu L et al. in his retrospective multicenter study proposed that 27% cases were at high risk of developing seizures with hypoxia being the most important risk factor. Shock, sepsis, imipenem use, acute cerebrovascular disease, traumatic brain injury, multiorgan dysfunction syndrome, and hypoglycemia are important risk factors as well.⁶⁵

Investigations for CNS symptoms in COVID -19:

Laboratory investigations included routine blood test, urine test, lumbar puncture, brain MRI, brain CT, pure tone threshold, electronystagmography, EEG, CT angiography of head and neck and CTP.^{54, 68} Another study showed that patients with elevated D-dimer levels present with neurological symptoms in COVID-19.⁷⁷

Management of CNS symptoms in COVID-19:

Dizziness in COVID-19 was treated with meclizine, benzodiazepine, steroids, vestibular rehabilitation.⁵⁶ For stroke, treatment modalities included apixaban, aspirin, intravenous t-PA, clopidogrel, clot retrieval, stent, and hemicraniectomy.^{63, 78} For seizures, antiepileptic drugs like phenytoin, valproic acid, levetiracetam, zonisamide were prescribed to the patients.⁷⁹ Ataxia was relieved by clonazepam.⁶⁶

Prognosis of CNS symptoms in COVID-19:

A retrospective study conducted by Eskandar EN et al. on 4711 COVID-19 positive patients showed that 12% patients had neurological manifestations. Out of these patients 44% patients had an altered level of consciousness, 4% patients had seizure, and 4% patients had other brain lesions. The remaining patients in this subgroup had normal level of consciousness. The patients who have had stroke and altered mentation had the highest mortality rate when compared with other COVID-19 positive patients i.e., 49% vs 24% and 40% vs 33%, respectively.⁸⁰

CONCLUSION

In the light of the available literature, it is evident that Novel Corona virus can invade nervous system both directly and indirectly and can produce a wide array of signs and symptoms in both CNS and PNS. It is therefore important that healthcare workers from around the globe must have ample knowledge of these neurological manifestations. As stated above from multiple studies, these neurological symptoms can even constitute the first presenting symptom in COVID-19 positive patients, therefore, the possibility of any patient

presenting with neurological manifestations to have concomitant SARS-CoV-2 infection should always be kept in mind. The need to further evaluate and assess more possible neurologic signs and symptoms associated with COVID-19 is therefore crucial for the better treatment and reduction in morbidity and mortality in all such patients. We therefore urge that more studies should be conducted on the above topic for better understanding and management of the disease.

ETHICAL APPROVAL:

Ethical approval was not a pre-requisite for this review article.

REFERENCES

- Zhu N, Zhang D, Wang W, Li X, Yang B, Song J, Zhao X, Huang B, Shi W, Lu R, Niu P. A novel coronavirus from patients with pneumonia in China, 2019. *New England Journal of Medicine*. 2020 Jan 24.
- Green A. Li wenliang. *The Lancet*. 2020 Feb 29;395(10225):682.
- World Health Organization. Pneumonia of unknown cause- China. Disease outbreak news. 5 January 2020 available at <https://www.who.int/csr/don/05-january-2020-pneumonia-of-unknown-cause-china/en/>.
- WHO Director-General's opening remarks at the media briefing on Covid-19-11 March 2020. Available at <https://www.who.int/dg/speeches/detail/Who-director-general-s-opening-remarks-at-the-media-briefing-on-covid-19-11-march-2020>.
- WHO Covid-19 Dashboard. Geneva: World Health Organization, 2020. Available online: <https://covid-19.who.int/> (last cited: [27 April 2021]).
- Niazkar M, Niazkar HR. Covid-19 outbreak: Application of multi-gene genetic programming to country-based prediction models. *Electronic Journal of General Medicine*. 2020 Sep 1;17(5).
- MW ML. Neurological manifestations of Hospitalized Patients with Covid-19 in Wuhan, China: a retrospective case series. 2020.
- Helms J, Kremer S, Merdji H, Clere-Jehl R, Schenck M, Kummerlen C, Collange O, Boulay C, FafiKremmer S, Ohana M, Anheim M. Neurologic features in severe SARS-CoV-2 infection. *New England Journal of Medicine*. 2020 Jun 4;382(23):2268-70.
- Jiang F, Deng L, Zhang L, Cai Y, Cheung CW, Xia Z. Review of the clinical characteristics of coronavirus disease 2019 (COVID-19). *Journal of general internal medicine*. 2020 May;35(5):1545-9.
- Mao L, Jin H, Wang M, Hu Y, Chen S, He Q, Chang J, Hong C, Zhou Y, Wang D, Miao X. Neurologic manifestations of hospitalized patients with coronavirus disease 2019 in Wuhan, China. *JAMA neurology*. 2020 Jun 1;77(6):683-90.
- Shereen MA, Khan S, Kazmi A, Bashir N, Siddique R. Covid-19 infection: Origin, transmission and characteristics of human coronaviruses. *Journal of advanced research*. 2020 Jul; 24:91-8.
- Verdecchia P, Cavallini C, Spanevello A, Angeli F. The pivotal link between ACE2 deficiency and SARS-CoV-2 infection. *European journal of internal medicine* 2020 Apr 20.
- Guan WJ, Ni ZY, Hu Y, Liang WH, Ou CQ, He JX, Liu L, Shan H, Lei CL, Hui DS, Du B. Clinical characteristics of coronavirus disease 2019 in China. *New England journal of medicine* 2020 Apr 30;382(18):1708-20.
- Hang C, Wang Y, Li X, Ren L, Zhao J, Hu Y, Zhang L, Fan G, Xu J, Gu X, Cheng Z. Clinical features of patients infected with 2019 novel coronavirus in Wuhan China. *The lancet*. 2020 Feb 15;395(10223):497-506.
- Meunier N, Briand L, Jacquin-Piqués A, Brondel L, Pénicaud L. Covid-19 induced smell and taste impairments: putative impact on physiology. *Frontiers in Physiology*. 2021 Jan 26;11:1882.
- Zhou Z, Kang H, Li S, Zhao X. Understanding the neurotropic characteristics of SARS-CoV-2: from neurological manifestations of COVID-19 to potential neurotropic mechanisms. *Journal of neurology*. 2020 Aug;267:2179-84.
- Baig AM, Khaleeq A, Ali U, Syeda H. Evidence of the COVID-19 virus targeting the CNS: tissue distribution, host virus interaction, and proposed neurotropic mechanisms. *ACS chemical neuroscience*. 2020 Mar 13;11(7):995-8.
- Bourgonje AR, Abdulle AF, Timens W, Hillebrands JL, Navis GJ, Gordijn SJ, Bolling MC, Dijkstra G, Voors AA, Osterhaus AD, van Der Voort PH. Angiotensin-converting enzyme 2 (ACE2), SARS-CoV-2 and the pathophysiology of coronavirus disease 2019 (COVID-19). *The Journal of pathology*. 2020 Jul;251(3):228-48.
- Labò N, Ohnuki H, Tosato G. Vasculopathy and coagulopathy associated with SARS-CoV-2 infection. *Cells*. 2020 Jul;9(7):1583.
- Koralnik IJ, Tyler KL. COVID-19: a global threat to the nervous system. *Annals of neurology*. 2020 Jul;88(1):1-1.
- Galán JT. Stroke as a complication and prognostic factor of COVID-19. *Neurologia (English Edition)*. 2020 May 29.
- McFayden JD, Stevens H, Peter K. The emerging threat of (micro)thrombosis in COVID-19 and its therapeutic implications. *Circulation research*. 2020 Jul 31;127(4):571-87.
- Acarli AN, Samanci B, Ekizoglu E, Çakar A, Şirin NG, Gündüz T, Parman Y, Baykan B. Coronavirus disease 2019 (COVID-19) from the point of view of neurologists: observation of neurological findings and symptoms during the combat against a pandemic. *Archives of Neuropsychiatry*. 2020 Jun;57(2):154.
- Bobker SM, Robbins MS. COVID-19 and headache: A primer for Trainees. *Headache : The journal of Head and Face pain*. 2020 Sep; 60(8):1806-11.
- Chan JL, Murphy KA, Sarna JR. Myoclonus and cerebellar ataxia associated with COVID-19: a case report and systematic review. *Journal of neurology*. 2021 Feb;22:1-32.
- Sedaghat Z, Karimi N, Gullian Barre syndrome associated with COVID-19 infection: a case report. *Journal of Clinical Neuroscience*. 2020 Jun 1; 76:233-5.
- Liguori C, Pierantozzi M, Spanetta M, Sarmati L, Cesta N, Iannetta M, Ora J, Mina GG, Puxeddu E, Balbi O, Pezzuto G. Subjective neurological symptoms frequently occur in patients with SARS-CoV-2 infection. *Brain, behavior, and immunity*. 2020 Aug 1;88:11-6.
- Paliwal VK, Garg RK, Gupta A, Tejan N. Neuromuscular presentations in patients with COVID-19. *Neurological sciences*. 2020 Sep 15:1-8.
- Klopfenstein T, Kadiane-Oussou NJ, Toko L, Royer PY, Lepiller Q, Gendrin V, Zayet S. Features of anosmia in COVID-19. *Medicine et Maladies infection*. 2020 Aug 1;50(5):436-9.
- Lechien JR, Chiesa-Estomba CM, De Siaty DR, Horoi M, Le Bon SD, Rodriguez A, Dequanter D, Blecic S, El Afia F, Distinguin L, Chekkoury-Idrissi Y. Olfactory and gustatory dysfunction as a clinical presentation of mild-to-moderate forms of the coronavirus disease (COVID-19): a multicenter European study. *European Archives of Oto-Rhino-Laryngology*. 2020 Aug;277(8):225-61.
- Kim GU, Kim MJ, Ra SH, Lee J, Bae S, Jung J, Kim SH. Clinical characteristics of asymptomatic and symptomatic patients with mild COVID-19. *Clinical microbiology and infection*. 2020 Jul 1;26(7):948-e1.
- Kacem I, Gharbi A, Harizi C, Souissi E, Safer M, Nasri A, Letaief H, Akkari M, Hechaichi A, Mrabet S, Dhauadi S. Characteristics, onset and evolution of neurological symptoms in patients with COVID-19. *Neurological Sciences*. 2021 Jan;42(1):39-46.
- Patel A, Charani E, Ariyanayagam D, Abdulaal A, Denny SJ, Mughal N, Moore LS. New-onset anosmia and ageusia in adult patients diagnosed with SARS-CoV-2 infection. *Clinical Microbiology and Infection*. 2020 Sep 1;26(9):1236-41.
- Romero-Sánchez CM, Diaz-Maroto I, Fernández-Díaz E, Sánchez-Larsen A, Layos-Romero A, García-García J, González E, Redondo-Peñas I, Perona-Moratalla AB, Del Valle-Pérez JA, Gracia-Gil J. Neurologic manifestations in hospitalized patients with COVID-19: the ALBACOV registry. *Neurology*. 2020 Aug 25;95(8):e1060-70.
- Rahimi K. Guillain-Barre syndrome during COVID-19 pandemic: an overview of the reports. *Neurological Sciences*. 2020 Sep 2:1-8.
- Gómez-Belda AB, Fernández-Garcés M, Mateo-Sánchez E, Madrazo M, Carmona M, Piles-Roger L, Artero A. COVID-19 in older adults: What are the differences with younger patients? *Geriatrics & gerontology international*. 2021 Jan;21(1):60-5.
- Itlaf Sr S, Fatima M, Salman Sr S, Salam JU, Abbas S. Frequency of neurological presentations of coronavirus disease in patients presenting to a tertiary care hospital during the 2019 coronavirus disease pandemic. *Cureus*. 2020 Aug;12(8).
- Bureau BL, Obeidat A, Dharwal MS, Jha P. Peripheral Neuropathy as a Complication of SARS-CoV-2. *Cureus*. 2020 Nov;12(11).
- Andalib S, Biller J, Di Napoli M, Moghini N, McCullough LD, Rubinos CA, Nobleza CO, Azarpazhooh MR, Catanese L, Elicer I, Jafari M. Peripheral nervous system manifestations associated with COVID-19. *Current neurology and neuroscience reports*. 2021 Mar;21(3):1-4.
- Kilic O, Kalcioğlu MT, Cag Y, Tuzysuz O, Pektas E, Caskurlu H, Cetin F. Could sudden sensorineural hearing loss be the sole manifestation of COVID-19? An investigation into SARS-CoV-2 in the etiology of sudden sensorineural hearing loss. *International Journal of Infectious Diseases*. 2020 Aug 1;97:208-11.
- Jacob J, Flannery W, Mostert C. Novel ENT triad of anosmia, ageusia and hearing impairment in COVID-19. *Internal Medicine Journal* 2020 Sep 1.
- Chern A, Famuyide AO, Moonis G, Lalwani AK. Bilateral Sudden Sensorineural Hearing Loss and Intralabyrinthine Hemorrhage in a Patient with COVID-19. *Otology & Neurology*. 2021 Jan; 42(1):e10.
- De Luca P, Cassandro E, Scarpa A, Cassandro C, Ralli M, Gioacchini FM, Re M, Chiarella G. Sudden sensorineural hearing loss and COVID-19 (commentary on "Could sudden sensorineural hearing loss be the sole manifestation of COVID-19? An investigation into SARS-CoV-2 in the etiology of sudden sensorineural hearing loss" by Osman Kilic, Mahmut Tayyar Kalcioğlu, Yasemin Cag, Ozan Tuzysuz, Emel Pektas, Hulya Caskurlu, and Ferihan Cetin). *International Journal of Infectious Diseases*. 2020 Dec 1;101:201-2.
- Luigetti M, Iorio R, Bentivoglio AR, Tricoli L, Riso V, Marotta J, Piano C, Primiano G, Zileri Del Verme L, Lo Monaco MR, Calabresi P. Assessment of neurological manifestations in hospitalized patients with COVID-19. *European journal of neurology*. 2020 Nov;27(11):2322-8.
- Fiani B, Covarrubias C, Desai A, Sekhon M, Jarrah R. A contemporary review of neurological sequelae of COVID-19. *Frontiers in Neurology*. 2020;11:640.
- Ponset-Megemont L, Paris P, Tronchere A, Salazard JP, Pereira B, Dallel R, Aumeran C, Beytout J, Jacomet C, Laurichesse H, Lesens O. High prevalence of headache during COVID-19 infection: a retrospective cohort study. *Headache: The journal of Head and Face Pain*. 2020 Nov;60(10):2578-82.
- Graham EL, Clark JR, Orban ZS, Lim PH, Szymanski AL, Taylor C, DiBiase RM, Jia DT, Balabanov R, Ho SU, Batra A. Persistent neurologic symptoms and cognitive dysfunction in non-hospitalized COVID-19 "Long hauler". *Annals of clinical and translational neurology*. 2021 May;8(5):1073-85.
- Huang C, Huang L, Wang Y, Li X, Ren L, Guo L, Liu M, Zhou X, Luo J. 6-month consequences of COVID-19 in patients discharged from hospital: a cohort study. *The Lancet*. 2021.
- Abu-Rumeileh S, Abdelhak A, Foschi M, Tuman H, Otto M. Guillain-Barré syndrome spectrum associated with COVID-19: an up-to-date systematic review of 73 cases. *Journal of neurology*. 2020 Aug 25:1-38.
- Ahmad I, Rathore FA. Neurological manifestations and complications of COVID-19: A literature review. *Journal of Clinical Neuroscience*. 2020 May 6.
- Flores-Silva FD, García-Grimshaw M, Valdés-Ferrer SI, Viguera-Hernández AP, Domínguez-Moreno R, Tristán-Samaniego DP, Michel-Chávez A, González-Duarte A, Vega Boada FA, Reyes-Melo I, Jiménez-Ruiz A. Neurologic manifestations in hospitalized patients with COVID-19 in Mexico city. *Plos one*. 2021 Apr 8;16(4):e0247433.
- Uygun Ö, Ertaş M, Ekizoglu E, Bolay H, Özge A, Orhan EK, Çağatay AA, Baykan B. Headache characteristics in COVID-19 pandemic-a survey study. *The journal of headache and pain*. 2020 Dec;21(1):1-0.
- Sampaio Racho-Filho PA, Magalhães JE. Headache associated with COVID-19: Frequency, characteristics and association with anosmia and ageusia. *Cephalalgia*. 2020 Nov;40(13):1443-51.
- Kong Z, Wang J, Li T, Zhang Z, Jian J. 2019 novel coronavirus pneumonia with onset of dizziness: a case report. *Annals of translational medicine*. 2020 Apr;8(7).
- Saniasyaya J, Kulasegarah J. Dizziness and COVID-19. *Ear, Nose & Throat Journal*. 2021 Jan;100(1):29-30.
- Malayala SV, Raza A. A case of COVID-19-induced vestibular neuritis. *Cureus*. 2020 Jun;12(6).
- Kotfis K, Roberson SW, Wilson JE, Pun BT, Ely EW, Jeżowska I, Jezińska M, Dabrowski W. COVID-19: What do we need to know about ICU delirium during the SARS-CoV-2 pandemic? *Anesthesiology intensive therapy*. 2020;52(2):132.
- Guan WJ, Liang WH, Zhao Y, Liang HR, Chen ZS, Li YM, Liu XQ, Chen RC, Tang CL, Wang T, Ou CQ. Comorbidity and its impact on 1590 patients with COVID-19 in China: a nationwide analysis. *European Respiratory Journal*. 2020 May 1;55(5).
- Vogrig A, Gigli GL, BnàC, Morassi M. unStroke in patients with COVID-19: Clinical and neuroimaging characteristics. *Neuroscience letters*. 2020 Dec 19:135564.
- Hernández-Fernández F, Sandoval Valencia H, Barbella-Aponte RA, Collado-Jiménez R, Ayo-Martin O, Barrera C, Molina-Neuvo JD, García-García J, Lozano-Setien E, Alechut-Rodríguez C, Martínez-Martín A. Cerebrovascular disease in patients with COVID-19: neuroimaging, histological and clinical description. *Brain*. 2020 Oct;143(10):3089-103.
- Zhang JJ, Dong X, Cao YY, Yuan YD, Yang YB, Yan YQ, Akdis CA, Gao YD. Clinical characteristics of 140 patients infected with SARS-CoV-2 in Wuhan, China. *Allergy*. 2020 Jul;75(7):1730-41.

62. Aggarwal G, Lippi G, Michael Henry B. Cerebrovascular disease is associated with coronavirus disease 2019 (COVID-19): a pooled analysis of published literature. *International Journal of Stroke*.2020 Jun;15(4):385-9.
63. Oxley TJ, Mocco J, Majidi S, Kellner CP, Shoirah H, Singh IP, De Leacy RA, Shigemastu T, Ladner TR, Yaeger KA, Skliut M. Large-vessel stroke as a presenting feature of Covid-19 in the young. *New England Journal of Medicine*.2020 May 14;382(20): e60.
64. Karimi N, Sharifi Razavi A, Rouhani N. Frequent convulsive seizures in an adult patient with COVID-19: a case report. *Iranian Red Crescent Medical Journal*. 2020 Mar 31;22(3).
65. Lu L, Xiong W, Liu D, Liu J, Yang D, Li N, Mu J, Guo J, Li W, Wang G, Gao H. New onset acute symptomatic seizure and risk factors in coronavirus disease 2019: a retrospective multicenter study. *Epilepsia*.2020 Jun;61(6): e49 -53.
66. Diezma-Martin AM, Morales-Casado MI, Alvarado NG, Bermejo-AV, Lopèz-Ariztegui N, Berrocal MS. Tremor and ataxia in COVID-19. *Neurologia (English Edition)*. 2020 Jul;35(6):409.
67. Meppiel E, Peiffer-Smadja N, Maury A, Bekri I, Delorme C, Desestret V, Gorza L, Hautecloque-Raysz G, Landre S, Lannuzel A, Moulin S. Neurologic manifestations associated with COVID-19: a multicenter registry. *Clinical Microbiology and Infection*.2021 Mar 1;27(3):458-66.
68. Scullen T, Keen J, Mathkour M, Dumont AS, Kahn L. Coronavirus 2019 (COVID-19)-associated encephalopathies and cerebrovascular disease: the New Orleans experience. *World neurosurgery* .2020 Sep 1;141: e437-46.
69. Varatharaj A, Thomas N, Ellul M, Davies NW, Pollak T, Tenorio EL, Sultan M, Easton A, Breen G, Zandi M, Coles JP. UK-wide surveillance of neurological and neuropsychiatric complications of COVID-19: the first 153 patients.
70. Durrani M, Kucharski K, Smith Z, Fien S. Acute transverse myelitis secondary to severe acute respiratory syndrome coronavirus 2 (SARS-COV-2): a case report. *Clinical practice and cases in emergency medicine*. 2020 Aug;4(3):344.
71. Poyiadji N, Shahin G, Noujaim D, Stone M, Patel S, Griffith B. COVID-19-associated acute hemorrhagic necrotizing encephalopathy: imaging features. *Radiology*.2020 Aug;296(2); E119-20.
72. Langley L, Zeicu C, Whitton L, Pauls M. Acute disseminated encephalomyelitis (ADEM) associated with COVID-19. *BMJ Case Reports CP*.2020 Dec 1; 13(12):e239597.
73. Chaumont H, Etienne P, Roze E, Couratier C, Roger PM, Lannuzel A. Acute meningoencephalitis in a patient with COVID-19. *Revue neurologique*. 2020.Jun 1;176(6):519-21.
74. Pun BT, Badenes R, La Calle GH, Orun OM, Chen W, Raman R, Simpson BG, Wilson-Linville S, Olmedillo BH, de la Cueva AV, van Der Jagt M. Prevalence and risk factors for delirium in critically ill patients with COVID-19(COVID-D): a multicentre cohort study. *The Lancet Respiratory Medicine*.2021.
75. Hussein M, Fathy W, Eid RA, Abdel-Hamid HM, Yehia A, Sheemy MS, Ragaie C, Dahshan A, Rizki HI, Magdy R. Relative Frequency and Risk factors in COVID-19 Related Headache in a Sample of Egyptian Population: A Hospital-Based study. *Pain Medicine*.2021 Feb 5.
76. Melmed KR, Cao M, Dogra S, Zhang R, Yaghi S, Lewis A, Jain R, Bilaloglu S, Chen J, Czeisler BM, Raz E. Risk factors for intracerebral hemorrhage in patients with COVID-19. *Journal of thrombosis and thrombolysis*.2021 May;51(4):953-60.
77. Karadaş Ö, Öztürk B, Sonkaya AR. A prospective clinical study of detailed neurological manifestations in patients with COVID-19. *Neurological Sciences* .2020 Aug;41(8):1991-5.
78. Qureshi AI, Abd-Allah F, Al-Senani F, Aytac E, Borhani-Haghighi A, Ciccone A, Gomez CR, Gurkas E, Hsu CY, Jani V, Jiao L. Management of acute ischemic stroke in patients with COVID-19 infection: Report of an international panel. *International Journal of Stroke*.2020 Jul;15(5):540-54.
79. Anand P, Al-Faraj A, Sader E, Dashkoff J, Abdennadher M, Murugesan R, Cervantes-Arslanian AM, Daneshmand A. Seizure as the presenting symptom of COVID-19:a retrospective case series. *Epilepsy & Behavior*.2020 Nov 1; 112:107335.
80. Eskandar EN, Altschul DJ, de La Garza Ramos R, CezayirliP, Unda SR, Benton J, Dardick J, Toma A, Patel N, Malaviya A, Flomenbaum D. Neurologic syndromes predict higher in-hospital mortality in COVID-19. *Neurology*.2021 Mar 16;96(11):e1527-38.

