

# Magnetic Resonance Evaluation of Normal Optic Nerve Sheath and Optic Nerve Diameter in Eastern Indian Paediatric Population- A Retrospective Study

Manoranjan Mohapatra<sup>1</sup>, Ranjan Kumar Sahoo<sup>1</sup>, Saroj Ranjan Sahoo<sup>2\*</sup>, Manoj Kumar G<sup>3</sup>

<sup>1</sup>Associate Professor; <sup>3</sup>Junior Resident, Department of Radiology, <sup>2</sup>Assistant Professor, Department of Surgery, Kalinga Institute of Medical science, KIIT University, Bhubaneswar, Odisha, India.

## ABSTRACT

**Background:** Prospective magnetic resonance imaging (MRI) of orbits in healthy paediatric population is difficult as it involves sedation or general anaesthesia in most of the cases. The data of normal value of healthy paediatric optic nerve and optic nerve sheath diameter is also scant in literatures for Indian paediatric population. The normal data will help in defining abnormal optic nerve such as congenital optic nerve hypoplasia, optic nerve atrophy and distended optic nerve sheath in raised intracranial pressure. **AIM:** The aim of our retrospective study is to define the normal value of optic nerve and optic nerve sheath diameter in MRI of paediatric Indian population.

**Methods:** 190 MRI studies of paediatric brain with normal radiology reports and no history of raised intracranial pressure were retrospectively reviewed by two senior radiologists using T2 weighted axial brain images.

**Results:** The mean optic sheath diameter and optic nerve diameter of 380 eye balls were 4.746 and 2.59 mm respectively. The age wise distribution of optic sheath diameter and optic nerve diameter were  $4.08 \pm 0.019$ ,  $2.05 \pm 0.608$  in 0-2-year age group,  $4.83 \pm 0.575$ ,  $2.54 \pm 0.456$  in 3-6-year age group,  $4.789 \pm 0.553$ ,  $2.704 \pm 0.447$  in 7-12-year age group, and  $4.82 \pm 0.567$ ,  $2.65 \pm 0.412$  in 13-18 years age group in mean (mm)  $\pm$  standard deviations respectively. Three hundred seventy-one (97%) optic sheath measurement of the 380 eye balls was below the threshold of 6 mm and about 352 (92%) optic nerve measurements out of 380 globes were having optic nerve thickness above 2 mm.

**Conclusions:** This normative data will help the ophthalmologist, clinician, neuro-ophthalmologist and radiologists for better quantitative evaluation of pediatric patient with vision abnormality.

**Keywords:** Children, diameter, magnetic resonance imaging, optic nerve, optic nerve sheath

Published Online: September 30' 2019

Received: 26.08.19


Accepted: 03.09.19

\*Corresponding Author

Dr. Saroj Ranjan Sahoo

Assistant Professor, Department of Surgery, Kalinga Institute of Medical science, KIIT University, Bhubaneswar, Odisha, India. Email: saroj.sahoo1@kims.ac.in

**Copyright:** © the author(s) and publisher. IABCR is an official publication of Ibn Sina Academy of Medieval Medicine & Sciences, registered in 2001 under Indian Trusts Act, 1882.


 This is an open access article distributed in accordance with the Creative Commons Attribution Non Commercial (CC BY-NC 4.0) license, which permits others to distribute, remix, adapt, build upon this work non-commercially, and license their derivative works on different terms, provided the original work is properly cited and the use is non-commercial

## INTRODUCTION

German anatomist Gustav Schwalbe, in the year 1870, demonstrated the continuation of subarachnoid space around the optic nerve with that of brain.<sup>1</sup> The dura mater of brain continues surrounding the optic nerve which is otherwise known as optic nerve sheath (ONS).<sup>2</sup> Many studies reveal that raised intracranial pressure is transmitted to cerebrospinal fluid around the optic nerve and distend the optic nerve sheath.<sup>3</sup> Visual acuity was found to be fully mature between the ages of 5 and the mid teenage years.<sup>4</sup> Detection of abnormal vision symptomatology is difficult to elicit in younger paediatric age group. Magnetic resonance imaging (MRI) is useful in paediatric patient as it provides better resolution of optic nerve, optic nerve sheath

and has sensitivity of 60-75% and specificity up to 90% in detecting optic nerve abnormality.<sup>5,6</sup> The optic nerve sheath shows maximum bulge 3 mm behind papilla. This position was recommended for the optic nerve sheath diameter (ONSD) measurements by many researchers.<sup>7</sup> The diagnosis of distended subarachnoid space around the nerve or abnormal thin optic nerve is sometimes challenging in paediatric case. Many articles have been published about the normative data of optic nerve sheath diameter by use of sonography, magnetic resonance imaging and computed tomography. However, few articles mentioned the diameter of the optic nerve thickness on MR imaging, especially in children. Measurement of the optic nerve diameter is

### Access this article online

Website: www.iabcr.org	Quick Response code 
DOI: 10.21276/iabcr.2019.5.3.14	

**How to cite this article:** Mohapatra M, Sahoo RK, Sahoo SR, Kumar MG. Magnetic Resonance Evaluation of Normal Optic Nerve Sheath and Optic Nerve Diameter in Eastern Indian Paediatric Population- A Retrospective Study. Int Arch BioMed Clin Res. 2019;5(3):44-47.

**Source of Support:** Nil, **Conflict of Interest:** None

essential for diagnosis of various optic nerve abnormalities in pediatric population such as optic nerve hypoplasia or optic nerve atrophy, hereditary optic neuropathy and optic nerve glioma.<sup>8,9</sup> The literature about the normative data of optic nerve and optic nerve sheath diameter in Indian paediatric population is scanty. Besides prospective study for normative MRI data of optic nerve diameter (OND) and optic nerve sheath diameter (ONSD) in healthy paediatric population is difficult due to requirement of sedation or general anaesthesia during MRI examination in most of the cases and high cost of the examination. Subjective determination of bilateral thinning or thickening of paediatric optic nerve or optic nerve sheath is more difficult than unilateral abnormality due to non-availability of comparison between healthy and abnormal side. This necessitated carrying out our retrospective study to establish the normative data of optic nerve and optic nerve sheath.

### METHODS

The present study was a retrospective analysis of MRI of brain of 190 (Asian race) pediatric cases done in our institution from January 2016 to April 2019, which included 104 males and 86 females with the age range of 2 months-18 years. The studies were done in 1.5T MRI machine (1.5T system, GE Signa, GE Healthcare) using head coil for the acquisition of the images. Cases were divided into four age groups: younger than 2 years, 2-6 years, 7-12 years, and 13-18 years. The cases with history of orbital/head trauma, optic nerve mass, optic nerve atrophy, raised intracranial pressure, intracranial hemorrhage/tumor, enucleation of one eye, phthisis bulbus, glaucoma or other ophthalmologic diseases such as microphthalmos, staphyloma, buphthalmos, and macrophthalmous were excluded from the study. The images showing movement artifacts, asymmetric sections of eyeballs and poor delineation of optic nerve complexes were also excluded from the study. The cases with history of headache, seizure, developmental delay, neck mass investigation and other than optic nerve lesions were included in our study. T2-weighted axial (3.5 to 4 mm thickness) images of brain were used for measurement of optic nerve and optic sheath diameter. The measurements were done with the aid of electronic calipers at 3 mm behind the papilla for optic nerve and optic sheath measurement (Fig. 1). Two experienced radiologists reviewed the MRI images of brain with normal findings and the data from both radiologists were averaged for statistical analysis. The data was analyzed using IBM SPSS (Statistical Package for Social Sciences) software version 22 for Microsoft windows. Values were expressed in terms of the mean and standard deviations (SDs).

The difference of measurements between male and female was analyzed using the independent t-test. The differences of the estimated values obtained by right and left sides were compared using paired t test. Correlation between different parameters was tested by Pearson correlation test. The *P* < 0.05 was considered statistically significant.

### RESULTS

Total 380 globes of 190 cases were studied. The mean age of cases was 10.21 years. One hundred four (54.7%) cases were males while eighty-six (45.3%) cases were females.

The right optic sheath diameter and optic nerve diameter (in mm) were 4.73±0.646 and 2.57±0.488 respectively. The left optic sheath diameter and optic nerve diameter (in mm) were 4.76±0.639 and 2.60±0.484 (in mean ±standard deviation) respectively. The combined mean and standard deviation of both side optic sheath and optic nerve diameter were 4.746 mm±0.642 and 2.59 mm±0.486 respectively. The right and left side measurements showed no statistically significant differences [Table 1]. The optic nerve sheath diameter and optic nerve diameter (with mean value in mm ±standard deviation) were 4.08±0.019, 2.05±0.608 in 0-2 year age group, 4.83±0.575, 2.54±0.456 in 3-6 year age group, 4.789±0.553, 2.704±0.447 in 7-12 year age group, and 4.82±0.567, 2.65±0.412 in 13-18 years age group respectively 484 [Table 2]. There was no statistically significant correlation between age, sex, right and left optic nerve diameter and optic nerve sheath diameter [Table 4]. Three hundred seventy one (97%) optic sheath measurements of the 380 eye balls were below the threshold of 6 mm and about three hundred fifty two (92%) measurements out of 380 eye balls were having optic nerve thickness above 2 mm. An increase in optic nerve and optic sheath diameter was observed with age [Table 3].

**Table 1: Difference between right optic nerve sheath diameter (RONSD) and left optic nerve sheath diameter (LONSD), right optic nerve diameter (ROND) and left optic nerve diameter eye (LOND)**

Parameters	Value	Combined Mean value of both eyes	P-value
RONSD	4.73±0.646	4.746±0.642	0.18
LONSD	4.76±0.639		
ROND	2.57±0.488	2.590±0.486	0.104
LOND	2.60±0.484		

**Table 2: The mean and standard deviation of RONSD, LONSD, ROND and LOND in age wise distribution.**

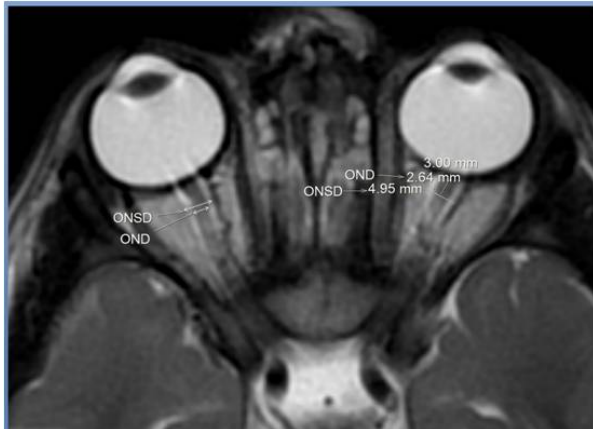Age Groups	0-2 years	3-6 years	7-12 years	13-18 years
Number	18	38	59	75
RONSD (mm) Mean±SD	4.072±0.913	4.83±0.592	4.75±0.594	4.82±0.549
LONSD(mm) Mean±SD	4.1±0.968	4.82±0.566	4.82±0.512	4.83±0.589
Combined Mean ONSD±SD of both eyes	4.08±0.0197	4.83±0.575	4.789±0.553	4.82±0.567
ROND (mm) Mean±SD	2.04±0.606	2.55±0.463	2.68±0.450	2.63±0.420
LOND(mm) Mean±SD	2.07±0.626	2.53±0.455	2.72±0.446	2.66±0.406
Combined Mean OND±SD of both eyes	2.059±0.608	2.54±0.456	2.704±0.447	2.65±0.412

**Table 3: Correlation of age with the right and left optic sheath diameter (ONSD) and optic nerve diameter (OND).**

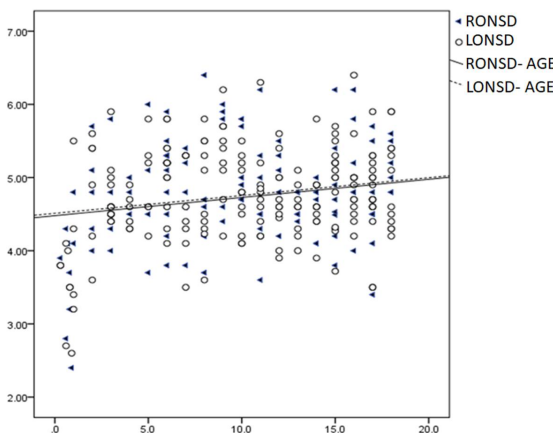
Parameters	Coefficient of correlations (r) WITH AGE	P VALUE
RONSD	0.224	0.0018
LONSD	0.222	0.0021
ROND	0.272	0.0015
LOND	0.280	0.00009

**Table 4: The means and standard deviations of RONSD, LONSD, ROND and LOND by gender.**

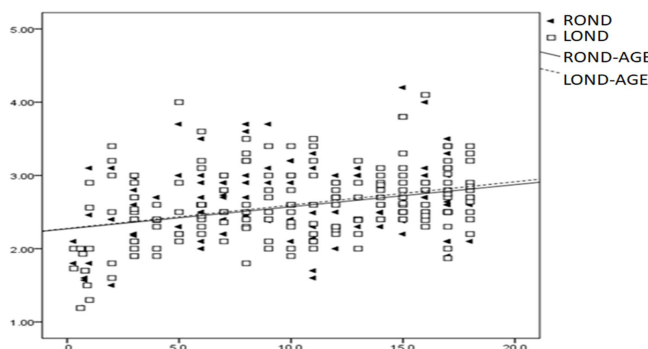
Parameters	Male N=104	Female N=86	P value
	Mean±SD	Mean±SD	
Age (years)	14.44±2.526	5.10±2.833	3.96
RONSD (mm)	4.82±0.585	4.62±0.699	0.053
LONSD (mm)	4.85±0.585	4.64±0.686	0.062
ROND (mm)	2.64±0.422	2.50±0.550	0.050
LOND (mm)	2.66±0.418	2.52±0.547	0.052



**Fig 1: Axial T2W image of brain shows the methods of measurement of optic nerve sheath diameter and optic nerve diameter at 3 mm behind papilla.**



**Fig 2: A Scatter plot of distribution of the optic nerve sheath diameter (ONSD) (mm) and age (years) shows ONSD is increasing with age.**



**Fig 3: A scatterplot of distribution of the optic nerve diameter (OND)(mm) by age (years) shows OND is increasing with age.**

## DISCUSSION

MRI imaging provides clear delineation of orbital structures and better resolution in comparison to ultrasound as latter is operator dependent and involves poor penetration and artifacts from tissue under observation.<sup>10,11</sup> Steinborn et al.<sup>12</sup> studied the optic nerve sheath diameter in clinically normal children and adolescents (5-18 years old) at 3 mm behind the papilla using axial T2-weighted MRI with additional thin section of the orbit showing mean optic nerve sheath diameter of 5.96±0.31 mm without significant differences among the observed age groups. The mean ONSD in our study was 4.746 mm, which was slightly lower than above study which could be due to inclusion of pediatric cases below 5 years of age in our study. In another study by P Janthaniami et al<sup>13</sup>, the mean optic nerve diameter and optic nerve sheath diameter in 42 studies were 2.5 mm and 5 mm respectively. The mean optic nerve diameter in our study was 2.5 which was matching with above study. However, the optic nerve sheath diameter was slight higher than our study which could be due to inclusion of lesser number of cases. Shofty et al.<sup>14</sup> measured the optic nerve sheath diameter at 10 mm anterior to optic foramina using axial T2-weighted thin (2.5 mm to 3 mm) MRI images of 84 healthy (control) pediatric cases below 18 years and found the mean ONSD as 3.1 mm, 3.41 mm, 3.55 mm and 3.56 mm in 0-3, 3-6, 6-12 and 12-18 years age group respectively. The above mean values were lower than our age group which may be explained by use of different methodology. In our study we obtained the measurement of ONSD at 3 mm behind papilla using 3.5 to 4 mm thick axial T2 weighted MRI imaging while Shofty et al. measured the optic nerve sheath at 10 mm anterior to optic foramina where the optic nerve is more tortuous for measurement in thick axial MRI images. Görkem et al.<sup>15</sup> measured ONSD at 5 mm behind the globe using MRI in 42 cases of pseudotumor cerebri and 30 cases of healthy pediatric population and found the mean ONSD as 3.2 mm in healthy control and 4.3 mm in pseudotumor cerebri which were lower than our value due to different methodology and few number of cases in the study. The Al-Haddad et al.<sup>8</sup> studied 211 Lebanese pediatric cases using thin section MRI image of orbit and observed the mean diameter steadily increased with the age from 1.35 ± 0.82 mm among patients younger than 6 months up to 2.26 ± 0.38 mm and 2.35 ± 0.40 mm for patients between 6 and 12 years of age and between 12 and 18 years respectively and the measurement were independent of sex or eye laterality. Our study revealed slight higher value of optic nerve diameter in comparison to above study which may be explained by use of thin (2 mm) section volumetric imaging of orbit by former researcher and different race of population in studies. Newer imaging modality such as diffusion tensor imaging (DTI) of optic nerve delineates the optic nerve intrinsic abnormality and detailed anatomy in comparison to conventional MRI. Decreased fractional anisotropy in DTI is found in case of multiple sclerosis with optic neuritis and optic nerve glioma in comparison to that in age-matched controls.<sup>16,17</sup> Use of reduced field-of-view diffusion tensor imaging of the optic nerve may serve as a biomarker of axonal and myelin damage in optic neuropathy for patients with retinitis pigmentosa.<sup>18</sup> Further large scale study using DTI and newer innovative imaging in addition to optic nerve and optic sheath diameter are needed for early detection of visual abnormality in young pediatric cases.

There are certain limitations to our study. Small numbers of cases in each age group are studied. True intracranial pressures were not recorded. We assumed normal intracranial pressure basing on normal MRI intracranial findings and clinical history. Most of the cases with normal MRI brain with no dedicated orbital imaging or volumetric imaging were included in the study. Further study with large number of cases with volumetric/thin section MRI imaging of orbit is needed.

## CONCLUSION

About 97% of 380 paediatric optic nerve sheath diameter were below the threshold of 6 mm and about 92% measurements were having optic nerve thickness above 2 mm. ONSD and OND measurement did not differ with eye laterality or sex. An increase in optic nerve and optic sheath diameter was observed with age. This normative data will help the ophthalmologist, clinician and radiologists for better quantitative evaluation of pediatric vision abnormality.

## REFERENCES

1. Schwalbe G. Untersuchungen über die Lymphbahnen des Auges und ihre Begrenzungen. *Archiv für mikroskopische Anatomie*. 1870;6(1):261-362.
2. Moretti R, Pizzi B. Ultrasonography of the optic nerve in neurocritically ill patients. *Acta Anaesthesiologica Scandinavica*. 2011;55(6):644-52.
3. Liu D, Kahn M. Measurement and relationship of subarachnoid pressure of the optic nerve to intracranial pressure in fresh cadavers. *Am J Ophthalmol* 1993; 116: 548-6.
4. Leat SJ, Yadav NK, Irving EL. Development of visual acuity and contrast sensitivity in children. *J Optom*. 2009;2(1):19-26.
5. Chawla B, Sharma S, Sen S, Azad R, Bajaj MS, Kashyap S, Pushker N, Ghose S. Correlation between clinical feature. s, magnetic resonance imaging, and histopathologic findings in retinoblastoma: a prospective study. *Ophthalmology*. 2012;119(4):850-6.
6. Schueler A, Hosten N, Bechrakis N, et al. High resolution magnetic resonance imaging of retinoblastoma. *Br J Ophthalmol*. 2003;87:330-5.
7. Vaiman M, Abuita R, Bekerman I. Optic nerve sheath diameters in healthy adults measured by computer tomography. *Int J Ophthalmol* 2015;8(6):1240.
8. Al-Haddad CE, Sebaaly MG, Tutunji RN, Mehanna CJ, Saaybi SR, Khamis AM, Hourani RG. Optic nerve measurement on MRI in the pediatric population: normative values and correlations. *Am J Neuroradiol*. 2018;39(2):369-74.
9. Gala F. Magnetic resonance imaging of optic nerve. *Indian J Radiol Imaging*. 2015;25(4):421.
10. Weigel M, Lagrèze WA, Lazzaro A, Hennig J, Bley TA. Fast and quantitative high-resolution magnetic resonance imaging of the optic nerve at 3.0 tesla. *Invest Radiol* 2006;41:83-86.
11. Shirodkar CG, Munta K, Rao SM, Mahesh MU. Correlation of measurement of optic nerve sheath diameter using ultrasound with magnetic resonance imaging. *Indian J Crit Care Med* 2015;19:466-70.
12. Steinborn M, Friedmann M, Hahn H et al. Normal values for transbulbarsonography and magnetic resonance imaging of the optic nerve sheath diameter (optic nerve sheath diameter) in children and adolescents. *Ultraschall Med* 2015;36:54-8.
13. Janthanimiti P, Dumrongpisutikul N. Pediatric optic nerve and optic nerve sheath diameter on magnetic resonance imaging. *Pediatr Radiol*. 2019:1-7.
14. Shofty B, Ben-Sira L, Constantini S et al. Optic nerve sheath diameter on MR imaging: establishment of norms and comparison of pediatric patients with idiopathic intracranial hypertension with healthy controls. *Am J Neuroradiol* 2012;33:366-9.
15. Gökem SB, Doğanay S, Canpolat M, Koc G, Dogan MS, Per H, Coşkun A. MR imaging findings in children with pseudotumor cerebri and comparison with healthy controls. *Childs Nerv Syst*. 2015;31(3):373-80.
16. Cauley KA, Filippi CG. Diffusion-tensor imaging of small nerve bundles: cranial nerves, peripheral nerves, distal spinal cord, and lumbar nerve roots-clinical applications. *Am J Roentgenol*. 2013;201(2):W326-35.
17. Filippi CG, Bos A, Nickerson JP et al. Magnetic resonance diffusion tensor imaging (MRDTI) of the optic nerve and optic radiations at 3T in children with neurofibromatosis type I (NF-1). *Pediatr Radiol*. 2012;42:168-74.
18. Zhang Y, Guo X, Wang M, Wang L, Tian Q, Zheng D, Shi D. Reduced field-of-view diffusion tensor imaging of the optic nerve in retinitis pigmentosa at 3T. *Am J Neuroradiol*. 2016;37(8):1510-15.

